

## Case Report

## Acute shoulder infection following acupuncture—A report of three cases

Wo-Jan Tseng<sup>a</sup>, Chih-Hung Chang<sup>b</sup>, Rong-Sen Yang<sup>c</sup>, Karl Wu<sup>b,c,\*</sup><sup>a</sup> Department of Orthopedics, National Taiwan University Hospital Hsinchu Branch, Hsinchu City, Taiwan, ROC<sup>b</sup> Department of Orthopedics, Far-Eastern Memorial Hospital, Taipei, Taiwan, ROC<sup>c</sup> Department of Orthopedics, National Taiwan University Hospital, Taipei, Taiwan, ROC

## ARTICLE INFO

## Article history:

Received 21 May 2013

Received in revised form

13 June 2013

Accepted 5 August 2013

Available online 16 November 2013

## Keywords:

acupuncture

infection

septic arthritis

## ABSTRACT

Worldwide, acupuncture is a popular alternative medicine for releasing pain, treating diseases, or promoting health. Although it is generally considered safe, a few complications have been reported. These complications ranged from minor side effects, such as pain, local hematoma formation, or the aggravation of symptoms, to serious complications including mechanical injuries, such as pneumothorax and severe infection requiring surgical treatment. In orthopedic clinics, reports of complications caused by acupuncture are rare. We present three cases who developed severe infection following acupuncture, leading to irreversible osteoarthritic changes in their glenohumeral joints. All of them mentioned a history of acupuncture therapy before their shoulder became swollen and hot and no other infection source could be detected. Possible explanations included: (1) breakdown of the sterile technique; (2) no consensus of acupoint or how deep the needle should be inserted; (3) patient's comorbidities, such as diabetes mellitus or previous shoulder pathology, were not considered. Although these three patients underwent debridement and proper management with antibiotics according to the culture data, eventually, they still progressed to severe glenohumeral joint destruction. Strict infection control guidelines should be established to lower this type of life-threatening complication.

Copyright © 2013, Taiwan Orthopaedic Association. Published by Elsevier Taiwan LLC. All rights reserved.

## 1. Introduction

Shoulder pain is a common problem that generally leads to musculoskeletal morbidity,<sup>1</sup> and acupuncture is one of the common treatments used in Asia to relieve the associated discomfort. Acupuncture involves procedures inserting thin, metallic needles into specific areas, known as the acupoints, which are located in different parts of the body. Some authors attribute their effects to beta-endorphin release in the lumbar spine and increased 5-hydroxytryptophan levels in the cerebrum, while other authors suggest that acupuncture may override the pain signal transmission process in the central nervous system,<sup>2</sup> or that it may free the energy (Qi) that was blocked, promoting its circulation.<sup>3</sup>

Acupuncture is generally thought to be a safe procedure when performed by well-trained practitioners.<sup>4</sup> Recent reviews reported adverse events, ranging from needle site pain and local hematoma formation,<sup>5</sup> to more severe mechanical injuries, such as

pneumothorax,<sup>6</sup> transmission of blood-borne infectious diseases, and deep soft tissue infections. The relationship between acupuncture and subsequent infectious complications raises significant concerns. A few articles reported a single case of septic arthritis<sup>7,8</sup> caused by acupuncture. In this article, we describe the first case series of acute shoulder infection complicating acupuncture, and advocate specific methods for infection control. Table 1 lists the treatment courses of the patients in our case series.

## 2. Case reports

## 2.1. Case 1

A 55-year-old woman with a long history of right shoulder pain had received one session of acupuncture for symptom relief. One week later, right shoulder swelling and erythematous changes had developed. She looked for help at several local clinics first, but in vain. She visited our outpatient clinic 45 days after her acupuncture therapy. Under the suspicion of inflammatory arthropathy, we arranged a series of examinations. Plain radiography revealed soft tissue swelling with inferior glenohumeral joint subluxation (Fig. 1A). Laboratory tests showed an initial white blood cell (WBC)

\* Corresponding author. Department of Orthopedics, Far-Eastern Memorial Hospital, Number 21, Section 2, Nanya South Road, Banqiao District, New Taipei City 220, Taiwan, ROC. Tel.: +886 2 89667000x2315; fax: +886 2 89777000.

E-mail address: [kevinwooo@gmail.com](mailto:kevinwooo@gmail.com) (K. Wu).

**Table 1**  
Demographic data and treatment courses of the three patients.

	Case 1	Case 2	Case 3
Age (y)	55	79	58
Sex	F	M	F
Underlying disease	Nil	DM	Nil
Acupuncture number	1	1	3
Interval (d)	7	8	8
Initial WBC (/μL)	16,180	16,040	9770
Initial CRP (mg/dL)	9.95	4.61	3.83
Debridement number	3	1	1
Pathogen	MRSA	MSSA	<i>H. parainfluenzae</i>
Antibiotic	Teicoplanin	Oxacillin	Unasyn
Final status	Hemi-shoulder arthroplasty	Being followed-up	Being followed-up
DASH score			
Before surgery	60	70	75
Currently	60 (31 mo)	60 (8 mo)	80 (7 mo)

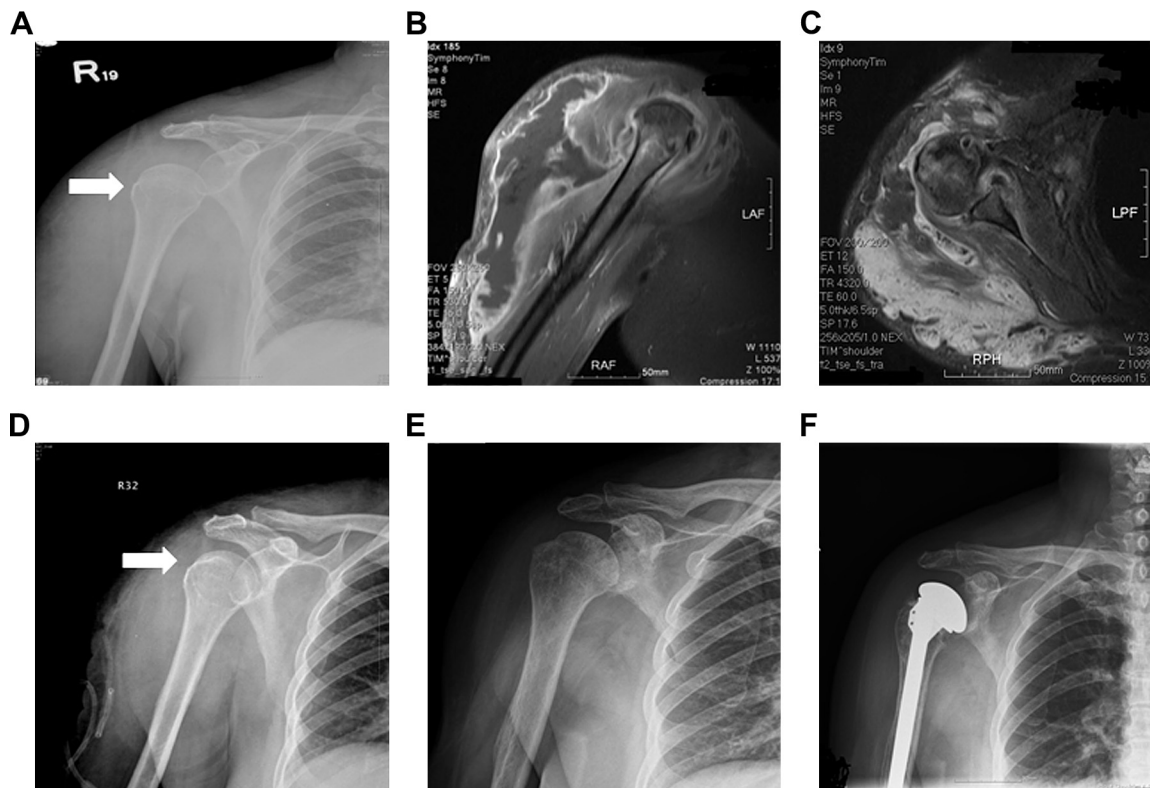
DASH = disabilities of the arm, shoulder and hand; DM = diabetes mellitus; *H. parainfluenzae* = *Haemophilus parainfluenzae*; MRSA = methicillin-resistant *Staphylococcus aureus*; MSSA = methicillin-sensitive *Staphylococcus aureus*.

count of 16,180/μL with predominant neutrophils. The C-reactive protein (CRP) level was 9.95 mg/dL. Magnetic resonance imaging (MRI) studies found prominent abscess formation around the right shoulder joint (Fig. 1B and C). We performed open arthrotomy and debridement. Bacterial cultures obtained during the surgery yielded methicillin-resistant *Staphylococcus aureus* (MRSA). Intravenous teicoplanin (400 mg, once daily) was started according to the drug sensitivity tests. Due to persistent purulent discharge from the surgical wound, we performed repeated open debridements (three

times). Her wound condition improved and no more swelling was noticed. Lab examination reported a normal WBC count and CRP level. We completed 4 weeks of intravenous teicoplanin and another 2 weeks of oral antibiotic therapy with rifampicin (300 mg daily) and fusidic acid (250 mg, 3 times daily). Although we did not find further swelling or local heat over her right shoulder during follow-up, a decreased range of motions developed. Right shoulder osteoarthritic changes with joint surface destruction were noted on plain X-rays (Fig. 1E). Due to the progressive degenerative changes in her shoulder which influenced her daily activities, and no signs of active infection clinically, we performed hemi-shoulder arthroplasty 16 months after her first shoulder operation (Fig. 1F). Her shoulder Disabilities of the Arm, Shoulder and Hand (DASH) score was 60 at her last 2-year follow up and no signs of infection were noticed.

## 2.2. Case 2

A 79-year-old man with diabetes mellitus presented with right shoulder swelling pain. Before visiting our hospital, he had suffered from right shoulder discomfort for months and had undergone one session of acupuncture therapy to ease his symptoms. However, right shoulder swelling, high fever and erythematous changes developed 8 days later. Laboratory data showed a WBC count of 16,040/μL and a CRP level of 4.61 mg/dL. MRI revealed shoulder joint capsule bone marrow enhancement, and intramuscular mass surrounding the biceps muscle. Under the impression of septic arthritis and pyomyositis, we performed open arthrotomy and debridement, and intraoperative bacterial culture yielded methicillin-sensitive *Staphylococcus aureus* (MSSA). Intravenous



**Fig. 1.** Case 1. The 55-year-old female suffered from right shoulder septic arthritis following acupuncture. (A) Anteroposterior radiograph shows right shoulder subluxation (white arrow); (B) T1 coronal magnetic resonance imaging (MRI) view; (C) T2 cross MRI view shows huge soft tissue abscess formation; (D) postoperative anteroposterior radiograph reveals spontaneous reduction of subluxation (white arrow); (E) anteroposterior radiograph taken 1 year after the episode. The glenohumeral joint shows sclerotic changes with subchondral cyst formation; and (F) anteroposterior radiograph of the right shoulder. The patient underwent shoulder hemi-arthroplasty 16 months later.

oxacillin (2 g every 4 hours) was applied for 3 weeks, followed by oral cephalexin (1 g every 6 hours) for another 2 weeks. The infection was controlled with antibiotics treatment.

### 2.3. Case 3

A 58-year-old female presented with right shoulder swelling and pain. Before her visit, she suffered from prolonged right shoulder pain and underwent three sessions of acupuncture therapy. Although no fever was noticed, septic arthritis was suspected due to swelling and local heat over her right shoulder. Plain X-ray revealed degenerative changes of the right humeral head with joint incongruence (Fig. 2A). Laboratory examination reported a WBC count of 9770/ $\mu$ L and a CRP level of 3.83 mg/dL. MRI showed thickened capsular synovium with contrast enhancement and the formation of a subdeltoid fluid sac (Fig. 2B and C). We performed open debridement and bacterial culture yielded *Haemophilus parainfluenzae*. We prescribed Unasyn (1.5 g, every 6 hours) for 3 weeks then oral Augmentin (1 g, every 12 hours) for management. Although there was subsidence of the shoulder swelling, progressive arthritic changes were revealed in the plain films taken 5 months later.

### 3. Discussion

Between May 2009 and May 2011, we noted several cases of acute shoulder infection in our orthopedic clinic; three of the patients mentioned a history of acupuncture therapy before the onset of swelling and local heat in the shoulder. Acute arthritic infection is a joint infectious condition that evolves over hours or days. The symptoms include pain, swelling, and a restricted range of motion. The most common etiology of septic arthritis of the shoulder is hematogenous dissemination, but its incidence has decreased due to modern antibiotics that help treat the source of infection. The percentage of other causes, including trauma, surgery, and injections around the shoulder, has increased.<sup>9</sup> In our case series, all patients suffered from shoulder pain for a long time and chose acupuncture as their first remedy. Case 3 received acupuncture three times before visiting our orthopedic clinic. Although none of the three patients could remember the exact acupoints where the practitioners inserted the needle, they recalled only simple skin disinfection with alcohol pads before acupuncture and the practitioners did not wear disposable gloves. No other active sources of infection could be detected in routine laboratory or imaging studies and it was therefore thought highly probable that acupuncture was the etiology of the acute shoulder infection in these patients.

There are some critical points that may lead to acupuncture becoming the infection source. One is the lack of sterile conditions and the breakdown in aseptic techniques while performing this

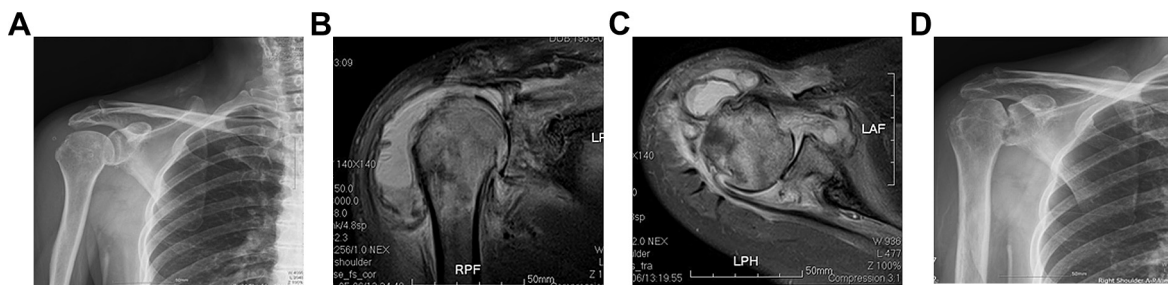
percutaneous procedure. Some practitioners do not disinfect the acupuncture needle in a standard way, and some do not pay much attention to the patient's skin condition. A few practitioners do not wear disposable gloves when carrying out the procedure and hold the needle with fingers that are not fully disinfected.<sup>10</sup>

A second point to be made is about the acupuncture procedure itself. According to bony landmarks, such as the greater tubercle of humerus, the acromion, or the clavicle, there are many acupoints scattered around the shoulder (Fig. 3). The real acupoints are hard to define; there is no agreement in different books. In addition, no consensus exists about the depth and the angle of needle insertion. The depth may range from several millimeters to centimeters and the angle may also vary. When performing acupuncture, one may go "too deep", so that the needle may puncture the shoulder joint or other profound tissues, and establish an open tract that facilitates the development of deep infection, if disinfection steps had not been followed properly.

Third, patients' comorbidities should be taken into consideration.<sup>11</sup> Individuals who are intravenous drug abusers, and those with diabetes mellitus, cardiovascular disorders,<sup>12</sup> previous shoulder pathology (e.g., rheumatoid arthritis, crystal arthropathy, inflammatory arthritis),<sup>9</sup> HIV infection, hypothyroidism, liver cirrhosis, and chronic hepatitis carriers, have all been reported to be more susceptible to infection.

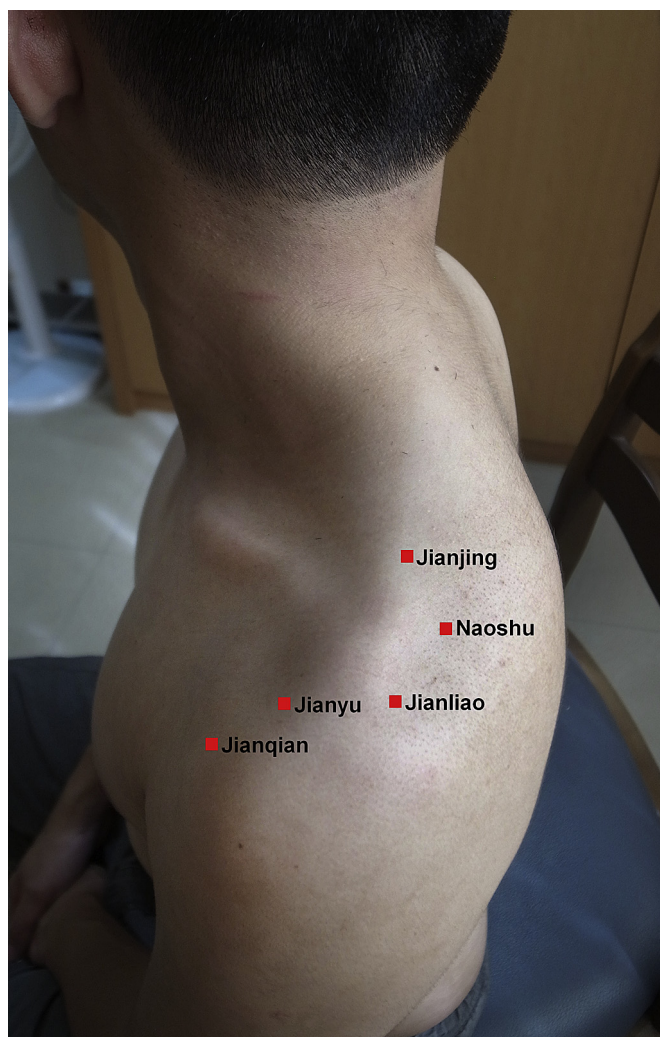After the diagnosis of acute shoulder infection was made, all three patients underwent open surgical debridement. Surgical treatment may shorten the length of hospitalization as compared to joint aspiration or antibiotic treatment alone.<sup>13</sup> We monitored the patients' peripheral white cell counts, their erythrocyte sedimentation rate and CRP, and noticed that all these parameters improved with proper antibiotics management according to results from bacterial cultures. Even though symptoms improved after debridement, progression to glenohumeral joint destruction occurred in two of the patients.

The bacterial culture of Case 3 yielded *Haemophilus parainfluenzae* (*H. parainfluenzae*). *H. parainfluenzae* is the normal inhabitant of oral mucosa, the gastrointestinal tract, and the urinary tract. Although it is not a common pathogen associated with bone and joint infection, a few cases were reported in the literature review. Khor et al<sup>14</sup> reported two cases of spine and sacroiliitis osteomyelitis, respectively, and summarized another 10 case reports with skeletal infection caused by *H. parainfluenzae*. Timothy et al<sup>15</sup> reported a case of acromioclavicular septic arthritis without any predisposing factors. Although these authors assumed the hematogenous spread to be via predisposing factors, such as tooth extraction or gastroscopy, not all cases had the risk factors. In Case 3, we thought that the *H. parainfluenzae* infection may be due to a contaminated needle inserted over her shoulder, or the insidious infection inoculated around the shoulder and the barrier was breakdown by the acupuncture procedure.



**Fig. 2.** Case 3. The 58-year-old woman was diagnosed with septic arthritis of the shoulder following acupuncture. (A) Initial plain film taken in our clinic. Bony destruction over the greater tubercle and glenohumeral joint was noted; (B) and (C) MRI in coronal and axial sections showed pus formation surrounding the shoulder joint; and (D) progressive arthritic changes were revealed in the plain film taken 5 months later.





**Fig. 3.** Common acupoints for treating shoulder pain: (1) Jianjing: above the nipple directly, the highest portion of the shoulder; (2) Naoshu: above the posterior axillary fold directly, a depression fossa inferior to the scapular spine; (3) Jianliu: posteroinferior corner of acromion; (4) Jianyu: anteroinferior corner of acromion; and (5) Jianqian: the midpoint between the anterior axillary fold and the Jianyu acupoints.

Therefore, great attention should be paid to the prevention of adverse events that could follow acupuncture. First, we would like to emphasize the importance of the concept of an aseptic technique. Scrupulous hygienic hand disinfection could remove the transient contamination with microflora originating from previous patients.<sup>16</sup> Changing gloves for every patient is crucial and patient selection is also essential. Skin should be washed and disinfected with alcohol (70% ethanol or isopropanol) near the needle insertion site. Other protective equipment should also be taken into consideration, including wearing suitable clothes to avoid the spread of the infection. There should also be management of clinical and related waste, and environmental hygiene and spills.<sup>17</sup> The authority concerned must focus on implementing proper infection

control guidelines,<sup>18</sup> including national standards in periodic practitioner health examinations to detect pathogen colonization, audits of premises and practices, holding educational seminars, and using posters or video clips to underline the importance of hygiene and patient safety.

The limitations of this case series are that we could not obtain the actual acupuncture conditions for our patients, such as the acupoints that the practitioner chose, the depth and angle of needle insertion, and how the skin preparation was performed. We should also trace the origin of these patients, with the hope of avoiding possible infectious disease outbreaks caused by practitioners who are not aware of the possible dangers that emerge when hygiene guidelines are disregarded.

In conclusion, acupuncture has gained increasing acceptance as a form of alternative medicine in both Asian and Western countries, and is considered to be a safe procedure. We present three patients who developed severe infection after acupuncture, leading to irreversible osteoarthritic changes in their glenohumeral joints. Strict infection control guidelines should be established to lower this type of life-threatening complication.

## References

1. A. Bjelle. Epidemiology of shoulder problems. *Baillieres Clin Rheumatol* 3 (1989) 437–451.
2. L. Viola. A critical review of the current conservative therapies for tennis elbow (lateral epicondylitis). *Australas Chiropr Osteopathy* 7 (1998) 53–67.
3. S. Green, R. Buchbinder, S.E. Hetrick. Acupuncture for shoulder pain. *Cochrane Database Syst Rev* (2005). <http://www.mrw.interscience.wiley.com/cochrane/clsysrev/articles/CD005319/frame.html>.
4. B. Walsh. Control of infection in acupuncture. *Acupunct Med* 19 (2001) 109–111.
5. J.E. Park, M.S. Lee, J.Y. Choi, B.Y. Kim, S.M. Choi. Adverse events associated with acupuncture: a prospective survey. *J Altern Complement Med* 16 (2010) 959–963.
6. E. Ernst, A. White. Life-threatening adverse reactions after acupuncture? A systematic review. *Pain* 71 (1997) 123–126.
7. P.C. Woo, S.K. Lau, K.Y. Yuen. First report of methicillin-resistant *Staphylococcus aureus* septic arthritis complicating acupuncture: simple procedure resulting in most devastating outcome. *Diagn Microbiol Infect Dis* 63 (2009) 92–95.
8. A.E. Kirschenbaum, C. Rizzo. Glenohumeral pyarthrosis following acupuncture treatment. *Orthopedics* 20 (1997) 1184–1186.
9. C.J. Mathews, V.C. Weston, A. Jones, M. Field, G. Coakley. Bacterial septic arthritis in adults. *Lancet* 375 (2010) 846–855.
10. S.D. Chung, C.H. Chang, K. Wu, S.H. Chu. Post-acupuncture shoulder swelling. *QJM* 105 (2012) 281–282.
11. Y.G. Rhee, N.S. Cho, B.H. Kim, J.H. Ha. Injection-induced pyogenic arthritis of the shoulder joint. *J. Shoulder Elbow Surg* 17 (2008) 63–67.
12. D.L. Goldenberg. Septic arthritis. *Lancet* 351 (1998) 197–202.
13. E. Cleeman, J.D. Auerbach, G.G. Klingenstein, E.L. Flatow. Septic arthritis of the glenohumeral joint: a review of 23 cases. *J Surg Orthop Adv* 14 (2005) 102–107.
14. B.K. Khor, S.J. Liaw, H.C. Liao, C.C. Yang, M.H. Lee. Bone and joint infections caused by *Haemophilus parainfluenzae*. Report of two cases and literature review. *Clin Pract* 15 (2007) 206–208.
15. T.W. Carey, K. Jackson, R. Roure, B.E. Abell. Acromioclavicular septic arthritis: a case report of a novel pathogen. *Am J Orthop (Belle Mead NJ)* 39 (2010) 134–136.
16. P. Hoffman. Skin disinfection and acupuncture. *Acupunct Med* 19 (2001) 112–116.
17. R.J. Murray, J.C. Pearson, G.W. Coombs, J.P. Flexman, C.L. Gollidge, D.J. Speers, J.R. Dyer, et al. Outbreak of invasive methicillin-resistant *Staphylococcus aureus* infection associated with acupuncture and joint injection. *Infect Control Hosp Epidemiol* 29 (2008) 859–865.
18. P.C. Woo, S.K. Lau, S.S. Wong, K.Y. Yuen. *Staphylococcus aureus* subcutaneous abscess complicating acupuncture: need for implementation of proper infection control guidelines. *New Microbiol.* 26 (2003) 169–174.